

Northwestern

PRITZKER SCHOOL OF LAW

Journal of Criminal Law  
and Criminology

---

Attempts to Alter and Obliterate Finger-Prints

Author(s): Harold Cummins

Source: *Journal of Criminal Law and Criminology (1931-1951)*, Vol. 25, No. 6 (Mar. - Apr., 1935), pp. 982-991

Published by: Northwestern University Pritzker School of Law

Stable URL: <https://www.jstor.org/stable/1134845>

Accessed: 29-05-2019 14:38 UTC

---

JSTOR is a not-for-profit service that helps scholars, researchers, and students discover, use, and build upon a wide range of content in a trusted digital archive. We use information technology and tools to increase productivity and facilitate new forms of scholarship. For more information about JSTOR, please contact [support@jstor.org](mailto:support@jstor.org).

Your use of the JSTOR archive indicates your acceptance of the Terms & Conditions of Use, available at <https://about.jstor.org/terms>



JSTOR

Northwestern University Pritzker School of Law is collaborating with JSTOR to digitize, preserve and extend access to *Journal of Criminal Law and Criminology (1931-1951)*

# POLICE SCIENCE



FRED E. INBAU [Ed.]

---

## ATTEMPTS TO ALTER AND OBLITERATE FINGER-PRINTS

---

HAROLD CUMMINS\*

---

During the height of interest in the escaped Dillinger a physician epitomized in the few lines of a fictitious "want-ad" the hope of this and other fugitives to destroy or alter bodily marks which prove personal identity:

"Displeased with face, form, height, finger-prints, scars, coloring, personality, reputation. Will swap miscellaneous loot to surgeon who will alter appearance and personality to conform to different individual's characteristics. Lagniappe of a newly made wooden pistol given with accepted offer. Address: Hide-away Spillinger (formerly C31645211 Ind.) En Route Harbor of Safety, Abyssinia."<sup>1</sup>

The possible temporary protection afforded by changes in the externals by which ordinary sight recognition is made offers little satisfaction to the guilty, who must naturally be apprehensive, and especially in fear of eventual identification by means of finger-prints.

Dillinger's attempt to destroy the finger-print evidences of identity proved futile, as have similar attempts of others. The present article reviews the possibilities of such tampering with finger-prints, mainly

---

\*Department of Anatomy, Tulane University School of Medicine.

1. Submitted by Dr. Stephen F. Hale, of Mobile, to the New Orleans Times-Picayune, June 20, 1934.

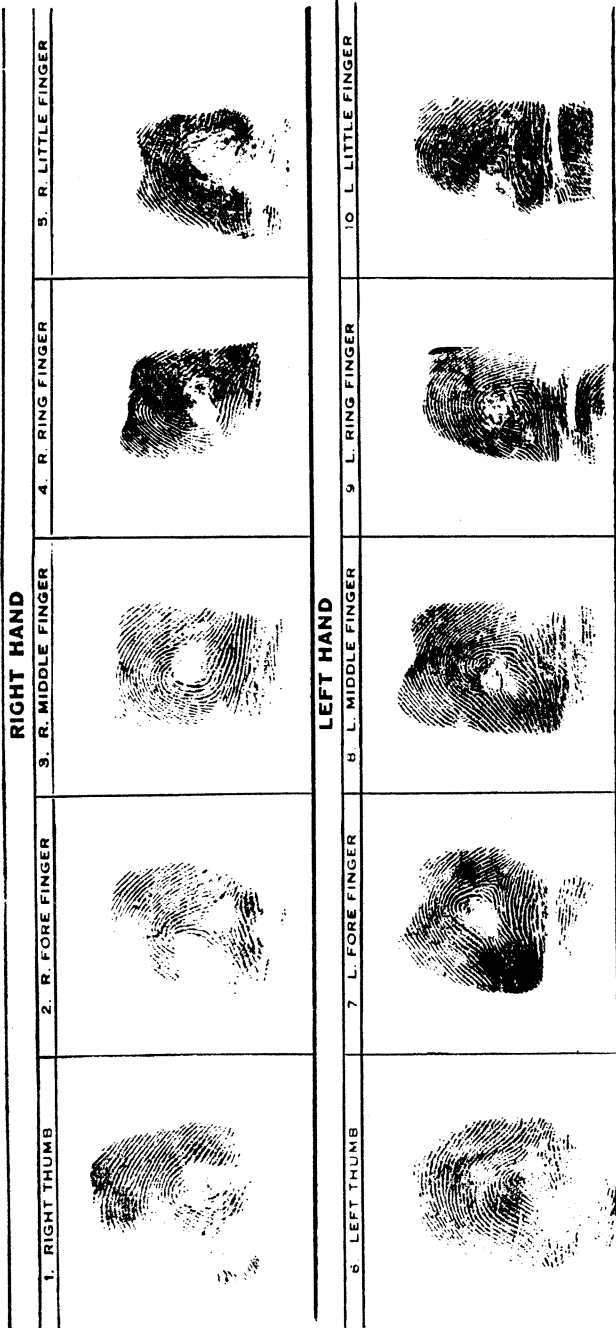


PLATE 1. The prints of John Dillinger, showing partial obliteration of pattern areas produced by application of acid.

based on the examples of John Dillinger,<sup>2</sup> Gus Winkler,<sup>3</sup> and Jack Klutas.<sup>4</sup>

### EXAMPLES

#### *Dillinger:*

Through the kindness of Mr. Charles M. Wilson, of the Scientific Crime Detection Laboratory, the writer has at hand the prints of Dillinger both before and after their partial obliteration. The first set is that recorded at Dayton, Ohio (September 22, 1933), while the second was made after his death, less than a year later (July 22, 1934). This second set shows the effects of attempted obliteration; it is here reproduced in plate 1.

Dillinger was said to have applied acid to the finger tips, and the prints bear out the probability of defacement by a corrosive agent. The reagent had been applied to the central pattern area, evidently with the thought that by destruction of this region the identity of the patterns would be lost. There is in most of the prints considerable cicatricial contraction, which not only deviates ridges in the familiar way but also, being extensive, alters the form and proportions of the patterns. While difficulty would be experienced in making up the formula for classification of the finger-print set, the extensive areas of the finger tips which have suffered no damage from the treatment bear, in each print, sufficient ridge details to establish the identification positively under comparison with the prior prints on record.

#### *Winkler:*

By courtesy of Mr. Al Dunlap the writer has had opportunity to study the prints of "Gus" Winkler, another who tried to destroy the identification value of finger-prints.

This case is particularly interesting in that the earlier set suggests a possible inspiration of the defacement appearing in the later finger-prints. In the first set there is a narrow longitudinal scar through the pattern of the right index, and this possibly accidental damage may have indicated to him how to proceed in the tampering which he later accomplished. The later prints exhibit alteration of

2. John Dillinger: desperado; murderer; escapee; shot by Federal agents, July 22, 1934, in Chicago.

3. "Gus" Winkler: murderer; racketeer; bank robber; shot and killed in Chicago October 9, 1933, by persons unknown.

4. Jack Klutas: murderer; racketeer; shot and killed by Cook County (Ill.) State's Attorney's Investigators, January 6, 1934.



PLATE 2. Left middle finger of "Gus" Winkler, before and after mutilation (prints at the left and right, respectively).

but four digits, all of the left hand, where the thumb alone remains intact. Without examination of the fingers in the flesh it is difficult to determine the manner in which the finger tips were treated; but the prints suggest that the fore- and middle fingers were simply slashed (longitudinally), while the ring- and little fingers may have been deeply abraded or torn. Whatever the means employed, the alteration is such as to introduce difficulties in formulation, as witnessed by the fact that the original correct formula

$$\begin{array}{c} 31 \quad O \quad 14 \\ \hline 20 \quad OI \quad 18 \end{array}$$

29 Oo 13 in the hands of the classifier of the altered prints. It

$$\begin{array}{c} 20 \quad Oo \\ \hline \end{array}$$

MI

should be obvious, however, that this confusion in the formula has no importance in the proof of identity, where even a single one of the prints furnishes conclusive testimony that the man is Winkler, and no other.

The left middle finger is of special interest in that some observers might perhaps interpret the effect as due to a well planned design toward converting the *Whorl* class of this pattern to *Loop*, with the aim of confusing the classification and filing of his record. The appearance of the damaged pattern does indeed suggest a loop, but it seems quite doubtful that this is more than a chance result, since the injury in this and the other three finger tips was accomplished by obviously crude methods, and with the evident objective of merely obliterating pattern areas. Enlarged prints of this digit, before and after the damage, are reproduced in plate 2, both for illustrating the above comment and for demonstration of the large number of ridge details which escaped injury, remaining as adequate identifying signs.

#### *Klutas:*

The third and last example to be mentioned is available also through the kindness of Mr. Dunlap. Jack Klutas' efforts toward defacement of patterns were the least effectual of all. This wanted man sought to deface patterns

$$\begin{array}{c} 32 \quad IIO \quad M \\ \hline 32 \quad OOI \end{array}$$

finger balls. Again, as in the Winkler case, there is some suggestion that accidental cuts (indicated in two prints of the earlier record, right index- and ring-fingers) might have prompted the heroic measure subsequently applied to all ten digits. I have no means of tracing

the history, however, and the possibility remains that these two digits were intentionally damaged, the more extensive cuts being made later, after realizing the futility of the first attempt. However that may be, the formulation of the damaged set tallies with the earlier record, hence neither classification nor, of course, identification is in the least affected by cuts in the finger tips.

#### MODES OF OBLITERATION

The structure and certain physiological properties of the fingertip skin should be first considered, since results naturally depend upon the character of the integument which is to be attacked by one or another destructive agent. The skin consists of two chief layers, a superficial one, *epidermis*, and a deeper connective tissue, *dermis* or *corium*. Epidermis is essentially cellular; its outer surface displays the ridges which compose the pattern, and the deep aspect is studded with minute bud-like extensions known as *epidermal papillae*. A close interlocking of the epidermis and dermis is effected by this irregularity, the connective tissue of the latter layer being mortised in by the elevation of *dermal papillae*, which form a negative counterpart of the epidermal modeling. Details of individual ridges and their arrangements in particular configurations are but a superficial expression of the fundamentally more important papillary level of the epidermis and dermis. Actual measurements of the fingertip skin, in sections prepared for microscopical examination, show that its depth from the surface through this level is about 1 mm. Thus, in destruction of the skin by any of the methods mentioned below this entire thickness must be removed, to ensure against restoration of ridges.

Finger-print workers are familiar with evidences in prints of occupational and accidental injuries to the finger tips. The narrow scar of a cleanly healed cut, for example, is a fairly frequent occurrence, its effect on the ridges being a negligible line of interruption of their courses, often associated with bending or puckering as they abut the scar. Wider tears and areas of former suppuration exhibit correspondingly more extensive replacement by scar tissue, in which there may appear no trace of the ridges formerly occupying the site. From these and similarly well known sources of injury to patterns we pass to consideration of methods which might be employed with the intention to frustrate identification.

In reviewing possible means of destroying the ridge texture it appears that they may be reduced to **three main classes: (1) Cor-**

rosion or searing, by action of strong acids, alkalis, or the cautery; (2) Abrasion, by the use of rasping devices; (3) Cutting, including vertical incisions, paring or tearing of the skin.

As noted above, the injury must extend to a depth of at least about 1 mm., or with subsequent regeneration the ridges will reappear. Furthermore, the expanse of the injury must be far greater than is the case in Dillinger, Klutas and Winkler, for even if the central pattern area is removed the peripheral region remains for comparison with record prints. And it will be evident that even with an entirely successful effacement of all ten finger patterns, the individual concerned may still find only disappointment in evading identification!

#### FINGER-TIP TRANSPLANTATION

Among the popular misconceptions respecting finger-prints there is a common belief that criminals not infrequently resort to grafting the finger-tip skin, even to the extent of having complete sets of patterns transplanted. Between the extremes of credulous acceptance of fantastic tales of skin grafting and stubborn denial that any grafting involving finger-prints is even possible, a sober view of the situation demands examination of such facts as are available

The first recorded observation which has bearing on this subject is that of Galton,<sup>5</sup> who in 1896 reported his findings in what might be termed a "casual" graft of ridged skin. A man had been cutting cardboard with a sharp knife; in holding a rule for guiding the knife the thenar eminence was pressed upon it, slightly overlapping the edge. A piece of skin was inadvertently sliced off. This piece was immediately applied to the wound and tightly bandaged. Examination of the injury (30 years later!) showed that the slip of skin had been successfully engrafted—though replaced at right angles to its original direction, as shown by the alignment of ridges.

It is not a far stretch from this to intentioned transplanting, a remarkable case of which has been recently reported by Updegraff,<sup>6</sup> a plastic surgeon. His patient, the victim of severe burns of the hands, presented a right fore-finger with marked flattening and contraction. For building up the flattened terminal segment of this digit the area of the third interdigital pattern of the palm was excised and substituted for the finger-tip skin, which in turn was transplanted to

5. Galton, F., "Prints of Scars," 53 Nature 295 (1896).

6. Updegraff, H. L., "Changing of Fingerprints," (NS) 26 Amer. Jour. Surgery 533 (1934).



the denuded region of the palm. Both grafts proved successful, with the result that the subject will henceforth bear on his index finger the foreign pattern from the palm.

Comments by Updegraff are here quoted at length, so important is this case in showing the feasibility of finger-print transplantation, with its implication of means of deception.

“Skin grafts taken from one person and transplanted to another or taken from animals and transferred to humans are so seldom successful that they may be eliminated from consideration. Where the very rare case has been successful at first, ultimately the graft was replaced by scar tissue. Ordinary skin taken from other parts of the body, with the exception of the palms of the hands and the soles of the feet, does not contain the characteristic ridges and will not develop them on transplantation . . . The ridges do not appear completely for several months after transplantation and one should not be misled on seeing an early graft.

“If only plain impression prints are made the scars if present will not show. A complete roll print however will show the incision lines in certain cases, especially if recently made. The fact that the ordinary latent print is a plain impression print, makes this of special interest.

“It would be possible to repeat the change, especially if it were a case of covering or eliminating old prints on file. The simplest way would be to remove the skin and graft from some other part of the body, as many finger tips in manual labor types, show no ridges.

“Detection of such a subterfuge would entail the recognition of scars on the finger. If ridges were present in the suspected grafted area, inspection of the palms and soles [and toes] with the tell-tale scars would be sufficient evidence. If no ridges are present on the suspected fingers, the entire body, usually the thighs, would furnish evidence of areas having supplied the graft tissue.”

## DISCUSSION

In the face of known instances of finger-print obliteration, and as well the demonstration by Updegraff of transplantation, it is evident that identification workers must on occasion meet instances in which routine methods may fail in part. It does not follow, however, that standard procedures in identification lose effectiveness, or even that they are seriously hampered by any of the results of tampering which have come to light.

It is interesting to note that as long as thirty years ago Faulds<sup>7</sup> remarked, in the brief discussion of “imperfect” prints included in Chapter III of his book, that “A case of bad obliteration of the special patterns might be in itself a suspicious circumstance, and is now

7. Faulds, Henry, “Guide to Finger-Print Identification” (1905).

of frequent occurrence." He does not follow the point further, leaving his readers with the thought that even in the formative period of finger-print identification there may have been cases paralleling the three here presented. Significantly enough, if there were such attempts they have proved no embarrassment to the growth of the method to its present widespread usefulness. It is imperative, nevertheless, to keep in mind that a badly scarred finger tip may be the result of design, not accident, and that surgery may be employed with such skill as to render difficult the detection of tampering.

Let us first consider the matter of latent prints as they would be affected by obliteration of finger-tip skin, assuming that tampering might be conceived as a preventive of leaving identifiable chance prints. Injuries sufficiently deep to erase permanently the ridge texture damage also the sweat glands, the secretion of which is responsible for the imprint left by contact of the finger tip. Slashes of the finger tip or areas of scar tissue produced by other means would thus reduce the expanse of the impression available for analysis of ridge details. But if the area of the imprint is large enough to include ridges at all the natural ridge characteristics would be supplemented by the numerous bendings, breaks and other artificial characteristics bordering the wound, introduced in its healing; these aid the identification instead of hindering it. Conceivably, the damage might extend over the whole finger-tip, eliminating chance impressions, other than featureless smudges. But the matter of latent impressions is after all a minor item, for it is in the establishment of identity of the individual whose prints are altered or partially obliterated that we are now interested.

Two steps in identification present themselves:

- (1) Location of the finger-print record in the file;
- (2) Proving the identity of the individual.

It is in the first step that difficulty may arise. The present discussion is based on the assumption that no one-finger method of registration is in operation in the identification files which are to be searched, thus imposing the most severe circumstances of classification and search. As instanced by the Winkler case, the classification based on a set having altered prints may direct the search for a prior record to the wrong sections of the file, or it may be impossible to formulate a set for proper direction of the search in the file. But in such instances (as Dillinger and Winkler) the identity of the criminal will be either known or suspected, hence narrowing the possi-

bility to one or several persons whose prints are then withdrawn for the comparison which yields evidentially final proof. It is at this point that definite pronouncement of identification may be made, and as noted in the cases here treated, identification is made as surely as if there had been no tampering with the prints. It would have been a different story if the whole series of finger patterns had been completely destroyed, leaving no traces for comparison with record prints. But here the very existence of such injury strengthens suspicion of the man, whose identification must then be sought from other aids. Updegraff suggests, because "plastic surgery is being utilized to defeat justice by changing facial contours, removing scars, etc.," that finger-prints should be supplemented by prints of the palms and soles. Such prints furnish adequate means of identification,<sup>8</sup> and their presence in the record would practically ensure against a defeated positive identification. It seems doubtful that present conditions call for this adjunct to finger-print records as a routine measure, however valuable it would prove in the as yet unrealized event that some offender mutilates all his finger patterns beyond recognition, effaces them entirely or appears with a complete grafted set which does not check with the record prints of the man he is suspected to be. To introduce the routine printing of palms and soles, or even palms alone, would entail a considerable amount of labor in printing; the prints would add materially to the bulk of the material filed; and to secure the full benefit of the prints, their separate classification would be necessary—all this as a provision for the chance that an individual might succeed in eliminating his finger-prints and other marks of identification as well. For the present, in the opinion of the writer at least, palm-prints and sole-prints are needed only in special cases: sole-prints for registration of the newborn,<sup>9</sup> where it is impossible to print the fingers satisfactorily; palm-prints and sole-prints otherwise only occasionally, as checks against chance impressions or as substitutes for finger-prints in cases where the latter are indecipherable or lost by amputations.

8. Inbau, Fred E., "Scientific Evidence in Criminal Cases. III. Finger-Prints and Palm-Prints," 25 *J. Crim. Law* 500, 515 (1934).

9. Cummins, Harold, "The Use of Foot-Prints and Finger-Prints as Identity Records in the Maternity," 81 *New Orleans Medical and Surgical Jour.* 493 (1929).